

Background Parenchymal Enhancement at Breast MR Imaging: Normal Patterns, Diagnostic Challenges, and Potential for False-Positive and False-Negative Interpretation¹

Catherine S. Giess, MD
Eren D. Yeh, MD
Sughra Raza, MD
Robyn L. Birdwell, MD

Abbreviations: BI-RADS = Breast Imaging Reporting and Data System, BPE = background parenchymal enhancement, NME = nonmass enhancement

RadioGraphics 2014; 34:234–247

Published online 10.1148/rg.341135034

Content Codes:  

¹From the Department of Radiology, Brigham and Women's Hospital, 75 Francis St, Boston, MA 02115. Recipient of a Cum Laude award for an education exhibit at the 2012 RSNA Annual Meeting. Received March 26, 2013; revision requested April 29 and received June 12; accepted June 24. For this journal-based SA-CME activity, C.S.G., S.R., and R.L.B. have disclosed financial relationships (see p 246); the other author, editor, and reviewers have no relevant relationships to disclose. **Address correspondence** to C.S.G. (e-mail: cgiess@partners.org).

See commentary on this article by Weinstein (pp 247–249).

SA-CME LEARNING OBJECTIVES FOR TEST 6

After completing this journal-based SA-CME activity, participants will be able to:

- Identify typical and unusual patterns of BPE at breast MR imaging.
- Describe the anatomic and physiologic influences on BPE.
- Discuss false-positive and false-negative interpretations due to BPE at screening and diagnostic breast MR imaging.

See www.rsna.org/education/search/RG

TEACHING POINTS

See last page

At magnetic resonance (MR) imaging, both normal and abnormal breast tissue enhances after contrast material administration. The morphology and temporal degree of enhancement of pathologic breast tissue relative to normal breast tissue form the basis of MR imaging's diagnostic accuracy in the detection and diagnosis of breast disease. Normal parenchymal enhancement at breast MR imaging is termed *background parenchymal enhancement* (BPE). BPE may vary in degree and distribution in different patients as well as in the same patient over time. Typically BPE is minimal or mild in overall degree, with a bilateral, symmetric, diffuse distribution and slow early and persistent delayed kinetic features. However, BPE may sometimes be moderate or marked in degree, with an asymmetric or nondiffuse distribution and rapid early and plateau or washout delayed kinetic features. These patterns cause diagnostic difficulty because these features can be seen with malignancy. This article reviews typical and atypical patterns of BPE seen at breast MR imaging. The anatomic and physiologic influences on BPE in women undergoing diagnostic and screening breast MR imaging are reviewed. The potential for false-positive and false-negative interpretations due to BPE are discussed. Radiologists can improve their interpretive accuracy by increasing their understanding of various BPE patterns, influences on BPE, and the potential effects of BPE on MR imaging interpretation.

©RSNA, 2014 • radiographics.rsna.org

Introduction

Lesion detection at contrast material-enhanced breast magnetic resonance (MR) imaging is primarily based on a lesion's vascularity relative to normal breast tissue. Diagnostic criteria for lesion assessment and management include both morphologic features and enhancement kinetics. Normal breast tissue can also enhance at breast MR imaging, and this enhancement of normal breast tissue is termed *background parenchymal enhancement* (BPE). Normal BPE can be classified as minimal (<25% of glandular tissue demonstrating enhancement), mild (25%–50% enhancement), moderate (50%–75% enhancement), or marked (>75% enhancement) (Fig 1) (1).

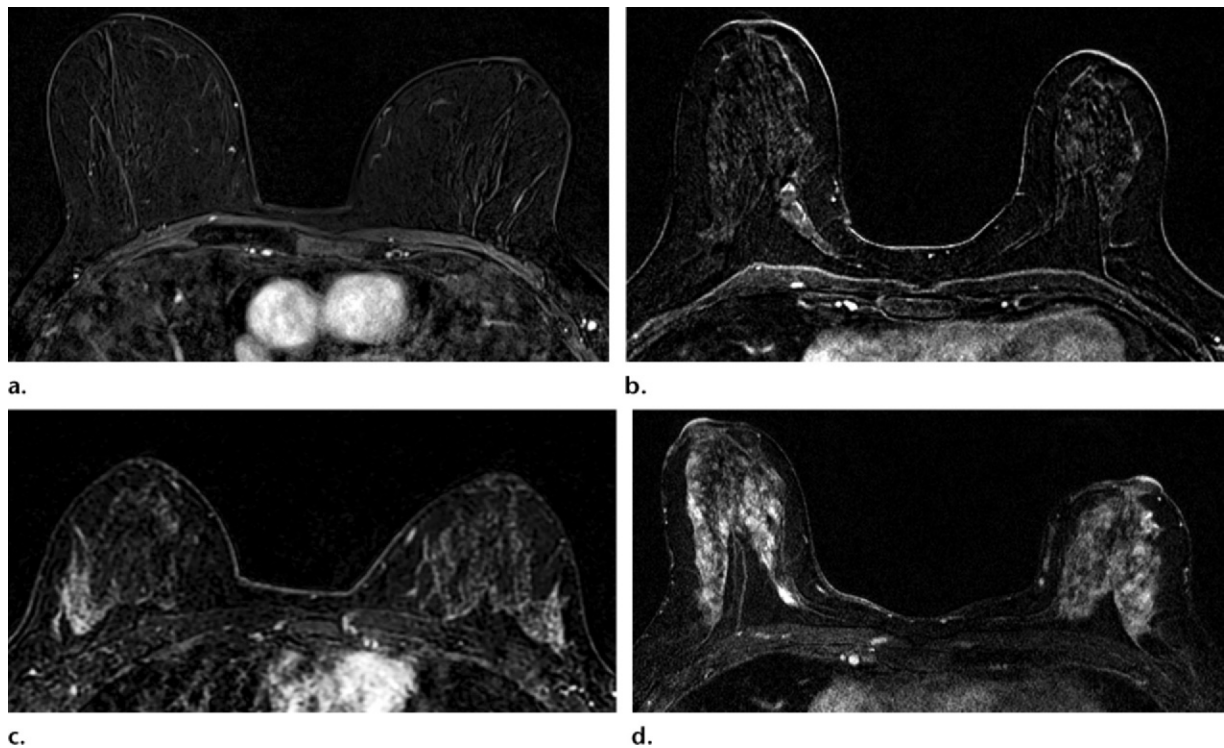


Figure 1. Axial contrast-enhanced T1-weighted fat-suppressed MR subtraction images in four different women show varying degrees of BPE: minimal BPE (<25% glandular enhancement) (a), mild BPE (25%–50% glandular enhancement) (b), moderate BPE (50%–75% glandular enhancement) (c), and marked BPE (>75% glandular enhancement) (d).

Although neither a description nor a classification of BPE was included in the first edition of the Breast Imaging Reporting and Data System (BI-RADS) MR imaging lexicon (2), clinical practice at our institution and at many others in the United States includes a description and classification of BPE seen at breast MR imaging. A description of BPE will likely be included in the next version of the BI-RADS lexicon. Just as breast tissue density can affect mammographic interpretation, the presence, pattern, and degree of BPE may affect the accuracy of MR imaging interpretation.

BPE is a dynamic process, varying among women and within the same woman over time (3). Typical BPE is bilateral, symmetric, and diffuse in distribution. The degree of overall enhancement is usually minimal or mild, with slow early and persistent delayed kinetic curves (Fig 2). These features generally cause no interpretive difficulties. However, when BPE is focal or asymmetric, it may be confused with nonmass enhancement (NME) (4). When it is diffuse and moderate or marked in degree, BPE may interfere with the ability to distinguish small breast lesions at MR imaging. This article describes the influences on BPE, illustrates typical and unusual patterns of BPE, and discusses the potential for false-positive and false-negative interpretations due to BPE at screening and diagnostic MR imaging.

MR Imaging Technique

The current breast MR imaging protocol at our institution includes prone imaging on an MR unit (Signa 1.5T or Signa HDxt 3.0T [General Electric Medical Systems, Milwaukee, Wis] or Magnetom Trio (Siemens Healthcare, Cary, NC) with the use of a dedicated breast surface coil (16-channel coil [Siemens], 8-channel coil [GE], or 7-channel coil [Invivo, Gainesville, Fla]). MR pulse sequences include a three-plane localizing sequence, an axial T2-weighted fat-suppressed fast spin-echo or T2-weighted short inversion time inversion-recovery sequence, and an axial fast spoiled gradient-echo T1-weighted non-fat-suppressed sequence before contrast material administration. Dynamic T1-weighted fat-suppressed three-dimensional fast spoiled gradient-echo sequences are then used in the axial plane before and four times after intravenous administration of gadopentetate dimeglumine (Magnevist; Bayer HealthCare, Wayne, NJ) at 0.1 mmol/kg. T1-weighted three-dimensional fast spoiled gradient-echo delayed contrast-enhanced MR images are acquired in the sagittal plane. Before 2010, dynamic MR images were acquired in either the sagittal or the axial plane, with delayed imaging performed in the orthogonal plane. Postprocessing, including subtraction axial images, maximum intensity projection, and computer-aided diagnosis

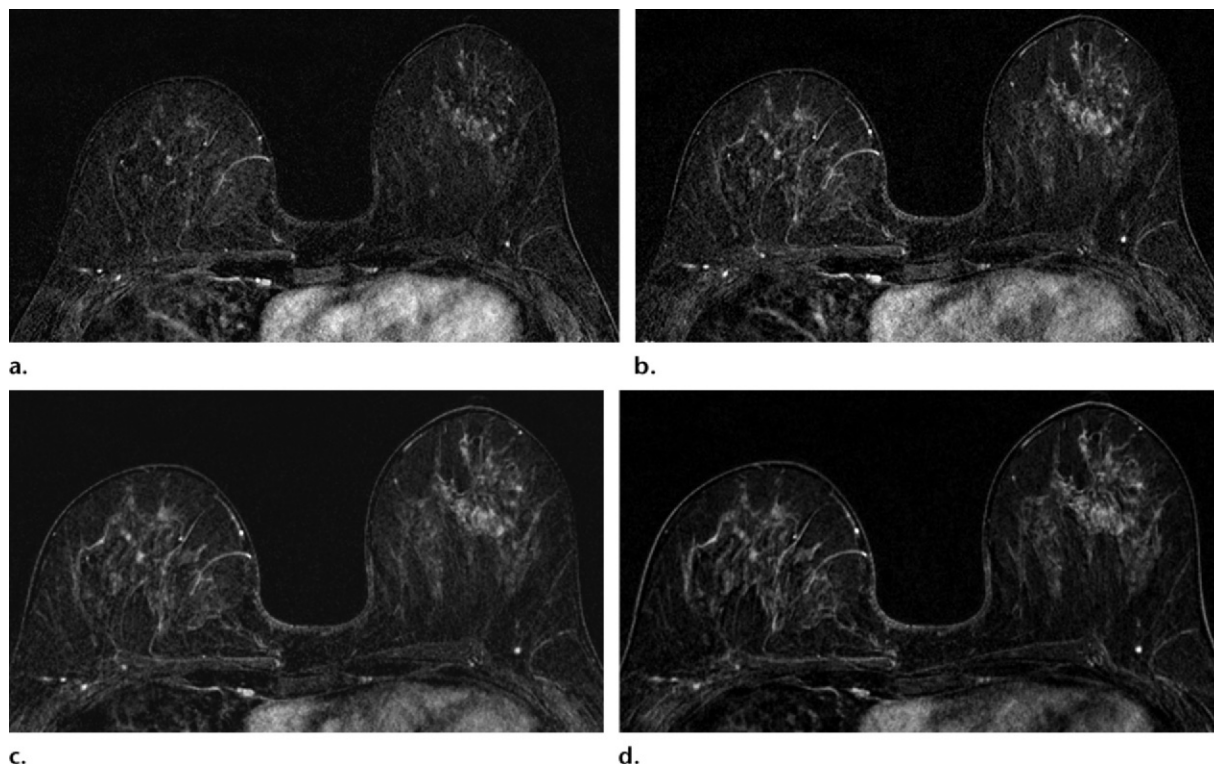


Figure 2. Axial contrast-enhanced dynamic T1-weighted MR subtraction images show typical BPE kinetic features with slow early and persistent delayed enhancement. Images are from the first contrast-enhanced series (**a**), second contrast-enhanced series (**b**), third contrast-enhanced series (**c**), and fourth contrast-enhanced series (**d**).

(CADstream; Merge Healthcare, Chicago, Ill), is routinely employed. The same protocol is used for both screening and diagnostic breast MR imaging. Supplemental breast imaging studies (mammography, ultrasonography [US], and positron emission tomography/computed tomography) are reviewed by the radiologist at the time of MR imaging interpretation.

Factors that Influence BPE

General Influences on Tissue Enhancement

Tissue enhancement at MR imaging depends on tissue vascularity and the permeability of the contrast agent into tissues. In a 2007 review article, Kuhl (5) listed a number of general factors that affect the degree and amount of tissue enhancement: the amount or concentration of the contrast agent (although the effects may not be linear), T1-weighted contrast of the pulse sequence used, baseline T1-weighted relaxation times of different breast tissues, inherent T1-weighted relaxivity of the contrast agent, and diffusion rate of the contrast agent. Specifically within the breast, the anatomy of the mammary vascular system and hormonal influences on the mammary tissue also affect the pattern and degree of BPE and are discussed in the following sections.

Vascular Supply to the Breast

The anatomy of the breast's arterial and venous systems influences the pattern of temporal enhancement. The arterial blood supply to the breast is through three major sources: (*a*) medially from perforating branches of the internal thoracic artery (also known as the internal mammary artery), (*b*) laterally from pectoral branches of the thoracoacromial artery and branches of the lateral thoracic artery, and (*c*) from lateral cutaneous branches of the intercostal arteries (Fig 3) (6). The arterial blood comes in peripherally to supply the central cone of the breast tissue. **Therefore, BPE commonly begins in the periphery of the lateral, medial, posterior, superior, and inferior breast tissue and gradually becomes apparent in the more central breast tissue.** The retroareolar region enhances last. This benign pattern of vascular inflow has been termed "picture framing" (7) (Fig 4). The venous drainage of the breast typically follows the arteries, mainly draining toward the axilla, and includes the perforating branches of the internal thoracic vein, tributaries of the axillary vein, and perforating branches of the posterior intercostal veins. There also is a superficial subdermal venous plexus that drains to the breast periphery and into vessels that join the internal thoracic, axillary, and internal jugular veins (6). Picture

Teaching
Point

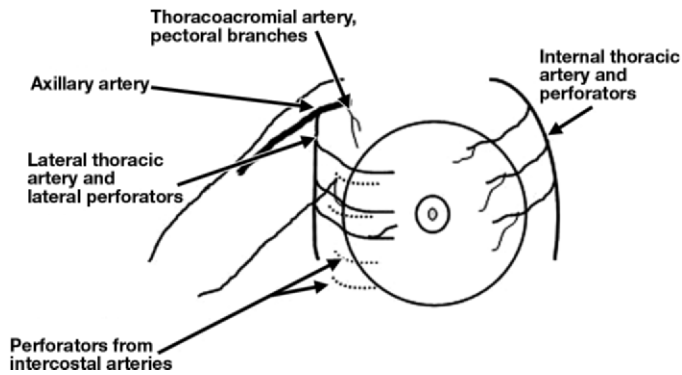


Figure 3. Drawing shows the arterial blood supply to the breast.

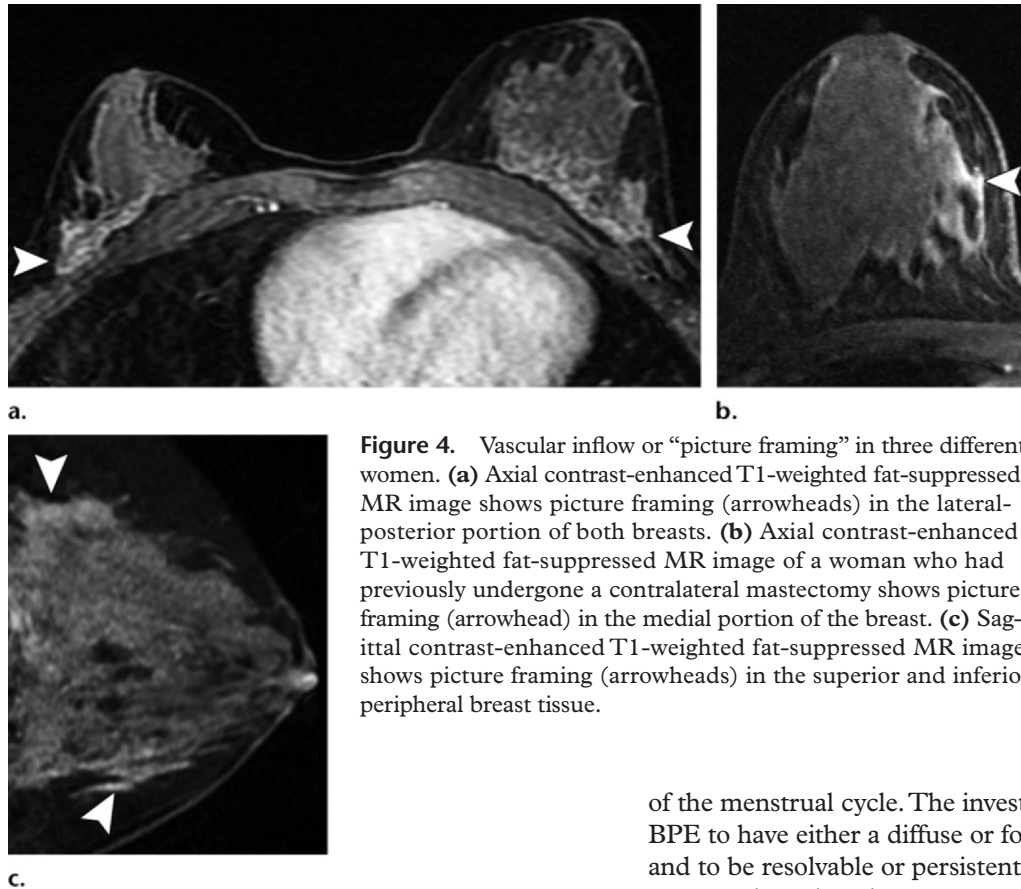


Figure 4. Vascular inflow or “picture framing” in three different women. **(a)** Axial contrast-enhanced T1-weighted fat-suppressed MR image shows picture framing (arrowheads) in the lateral-posterior portion of both breasts. **(b)** Axial contrast-enhanced T1-weighted fat-suppressed MR image of a woman who had previously undergone a contralateral mastectomy shows picture framing (arrowhead) in the medial portion of the breast. **(c)** Sagittal contrast-enhanced T1-weighted fat-suppressed MR image shows picture framing (arrowheads) in the superior and inferior peripheral breast tissue.

framing or vascular inflow can vary by patient or within the same patient at sequential MR imaging studies (Fig 5). It is likely that there are also variable differences in breast tissue enhancement caused by a patient’s cardiovascular status or hydration status.

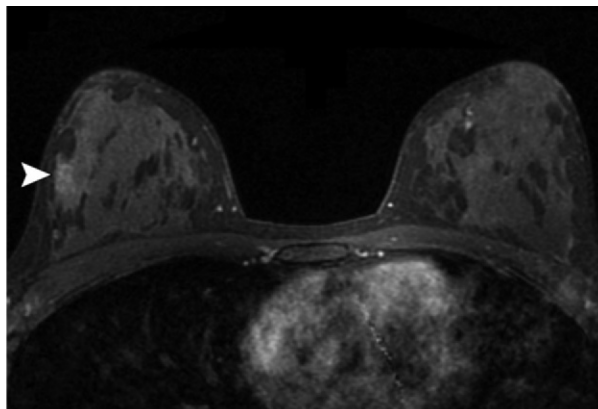
Effects of Endogenous Hormones

It was recognized early that the enhancement of normal breast tissue is variable and is affected by the hormonal milieu (3,8,9). In 1997, Kuhl et al (3) placed 20 healthy premenopausal women into two groups, imaging the first group once during each week of the menstrual cycle and the second group once per month for 4 months on a fixed day

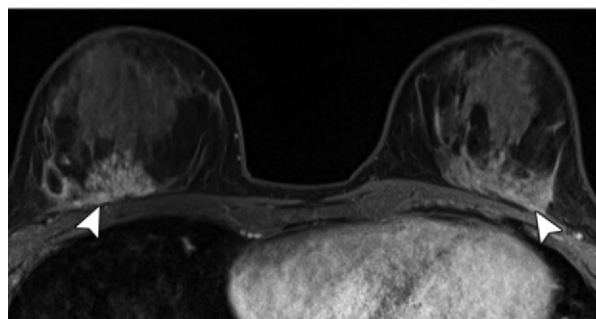
of the menstrual cycle. The investigators reported BPE to have either a diffuse or focal distribution and to be resolvable or persistent in both groups of women; the enhancing areas were 2–25 mm in size and included both irregular ill-defined areas and well-defined areas. Enhancement was highest during weeks 1 and 4 and lowest during week 2.

Müller-Schimpfle et al (8) evaluated the influences of menstrual cycle timing and patient age on the amount of BPE and reported that BPE was highest during days 21–28 and days 1–6, lowest during days 7–20, and higher in patients aged 35–50 years compared with younger and older women. Delille et al (9) found that the lowest amount of normal tissue enhancement occurred in the first half of the menstrual cycle and recommended that imaging be scheduled during days 3–14 to minimize interpretive difficulties. On the basis of the

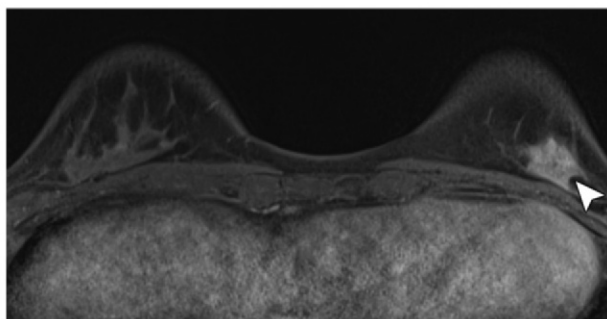
Figure 5. Migratory areas of vascular inflow in a 26-year-old woman with a history of Hodgkin disease treated with mantle radiation. **(a)** Screening axial contrast-enhanced T1-weighted fat-suppressed MR image obtained in 2010 shows picture framing in the lateral portion of the right breast (arrowhead). **(b)** Screening axial contrast-enhanced T1-weighted fat-suppressed MR image obtained in 2011 shows picture framing in the posterior portion of both breasts (arrowheads). **(c)** Screening axial contrast-enhanced T1-weighted fat-suppressed MR image obtained in 2012 shows asymmetric picture framing in the inferior portion of the left breast (arrowhead). The enhancement conformed to tissue planes and diminished at follow-up imaging.



a.

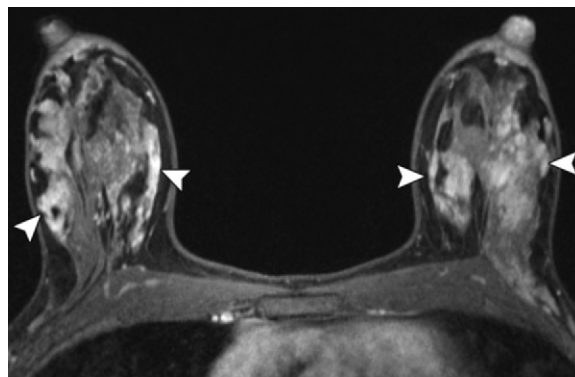


b.



c.

Figure 6. BPE in a lactating 37-year-old woman with a strong family history of breast cancer who underwent screening breast MR imaging. Axial contrast-enhanced T1-weighted fat-suppressed MR image shows areas of marked focal and regional heterogeneous BPE (arrowheads).



findings of these studies, **it is recommended that nonurgent breast MR imaging (such as screening or short-term follow-up imaging) should be scheduled during the 2nd week of the menstrual cycle (days 7–15).** For premenopausal patients with an irregular or absent cycle who may still be undergoing cyclical hormonal variations, Ellis (10) proposed testing serum progesterone levels to determine when patients are at the optimal time (the follicular phase) for MR imaging evaluation to minimize diagnostic uncertainties due to BPE.

In our clinical practice, premenopausal high-risk patients occasionally undergo surveillance MR imaging while breast-feeding because these patients often commence high-risk surveillance imaging during the childbearing years. Patients who are diagnosed with breast cancer while lactating also sometimes undergo breast MR imaging to evaluate the extent of disease or before undergoing neoadjuvant chemotherapy. Therefore, it is important to recognize the considerable effect that lactational changes may have on BPE (Fig 6). Several authors have reported brisk BPE in lactating patients, with rapid early enhance-

ment and delayed persistent or plateau-type enhancement (11,12). The increase in BPE, which has been attributed to increased vascularity and vascular permeability during lactation (11), may theoretically interfere with lesion detection. However, in two small series, investigators reported no impairment in cancer detection in lactating patients (12,13), although one patient's disease extent was overestimated because of surrounding enhancement (13). Anecdotally, the amount of lactation seems to affect the overall degree of BPE. The amount of gadolinium excreted into breast milk has been reported to be miniscule (14). On the basis of existing data, the American College of Radiology states that breast-feeding after contrast-enhanced MR imaging is considered safe; if the patient has concern regarding

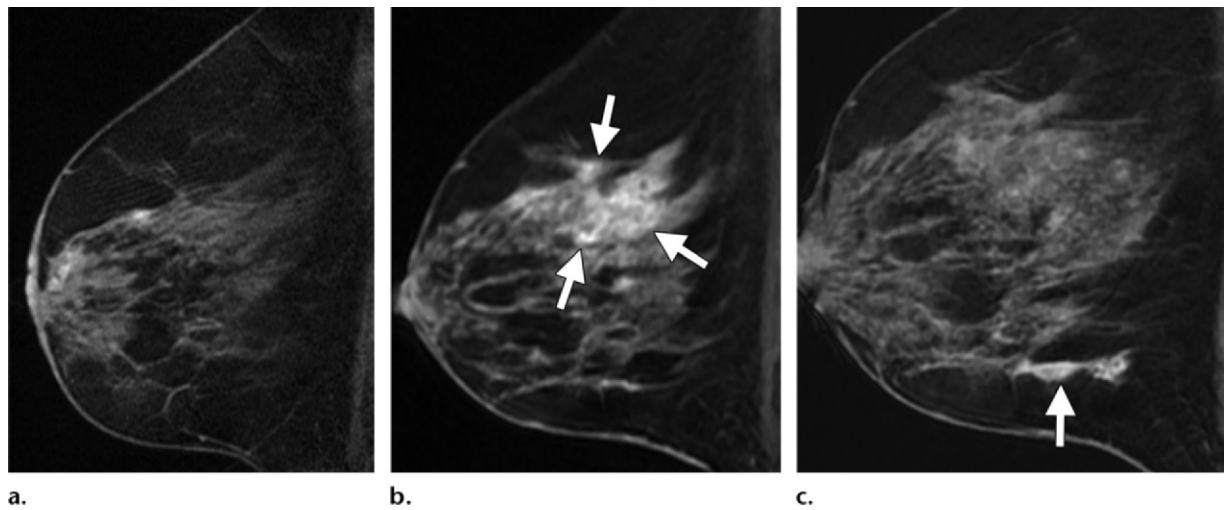


Figure 7. Effect of tamoxifen treatment on BPE in a 46-year-old high-risk woman with previous contralateral breast cancer that was treated with breast conservation therapy and tamoxifen. **(a)** Sagittal contrast-enhanced T1-weighted fat-suppressed MR image obtained during tamoxifen treatment in 2009 shows minimal BPE. **(b)** Sagittal contrast-enhanced T1-weighted fat-suppressed MR image obtained in 2010 after completion of tamoxifen treatment shows increased moderate BPE (arrows). **(c)** Sagittal contrast-enhanced T1-weighted fat-suppressed MR image obtained in 2011 shows mild BPE (arrow) in the inferior portion of the breast with rapid persistent kinetic features, a finding that was interpreted as a focal area of NME. An MR imaging–guided core-needle biopsy demonstrated normal breast tissue with gynecomastoid change. The finding resolved at follow-up MR imaging (not shown). Tamoxifen rebound may manifest as global or diffuse enhancement or focal areas of BPE.

her baby's oral ingestion of breast milk that contains minute amounts of gadolinium, she may be counseled regarding discarding breast milk for 24 hours after MR imaging (15).

Effects of Exogenous Hormones

In postmenopausal women, the degree of BPE seen at breast MR imaging is typically less than that seen in premenopausal women. King et al (16) evaluated 28 women who underwent breast MR imaging before and after menopause, and their study demonstrated that significant numbers of postmenopausal women showed a demonstrable decrease in BPE as well as in overall fibroglandular tissue. Conversely, when postmenopausal women undergo hormone replacement therapy (HRT), BPE may increase in amount, degree, and distribution. HRT typically results in bilateral, symmetric, persistent enhancement without suspicious delayed plateau or washout kinetic patterns (17). Delille et al (18) used the extraction-flow product, or the ratio of blood volume to the weight of tissue over time, to quantify tissue perfusion at breast MR imaging and reported that women who were undergoing HRT had an increase in breast tissue perfusion compared to women who were not receiving HRT.

Effects of Endocrine Therapy

Endocrine therapy with antihormonal treatment that includes selective estrogen receptor modulators (SERMs) or aromatase inhibitors is an

important part of treating estrogen/progesterone receptor-positive tumors. Because these agents act as antiestrogenic agents, they can decrease hormonal stimulation of the normal background breast tissue. King et al (19) reported a significant decrease in the amount of BPE, cysts, and fibroglandular tissue in patients who received tamoxifen therapy for breast cancer, and the effect on BPE was evident early in treatment (<90 days). Sometimes after a patient completes tamoxifen treatment, there may be an increase in BPE (Fig 7), a finding that has been termed *tamoxifen rebound* (C. Comstock, oral communication, ARRS Breast Imaging Symposium, September 2012). Tamoxifen rebound may manifest at MR imaging as global BPE or as more focal areas of BPE that can cause diagnostic difficulties. Another SERM, toremifene, has been used to treat mastalgia, and decreases in tissue enhancement at breast MR imaging have been reported with its use (20). King et al (21) have evaluated the effects of aromatase inhibitors on BPE, and their study demonstrated a decrease in BPE in 33.9% of postmenopausal patients with cancer that was treated with aromatase inhibitors. Investigators in a separate pilot study (22) evaluated the effect of high-dosage aromatase inhibitors on BPE in healthy postmenopausal women. They performed breast MR imaging examinations before and after 3 days of high-dosage aromatase inhibitor therapy and reported a statistically significant decline in the degree of BPE after treatment.

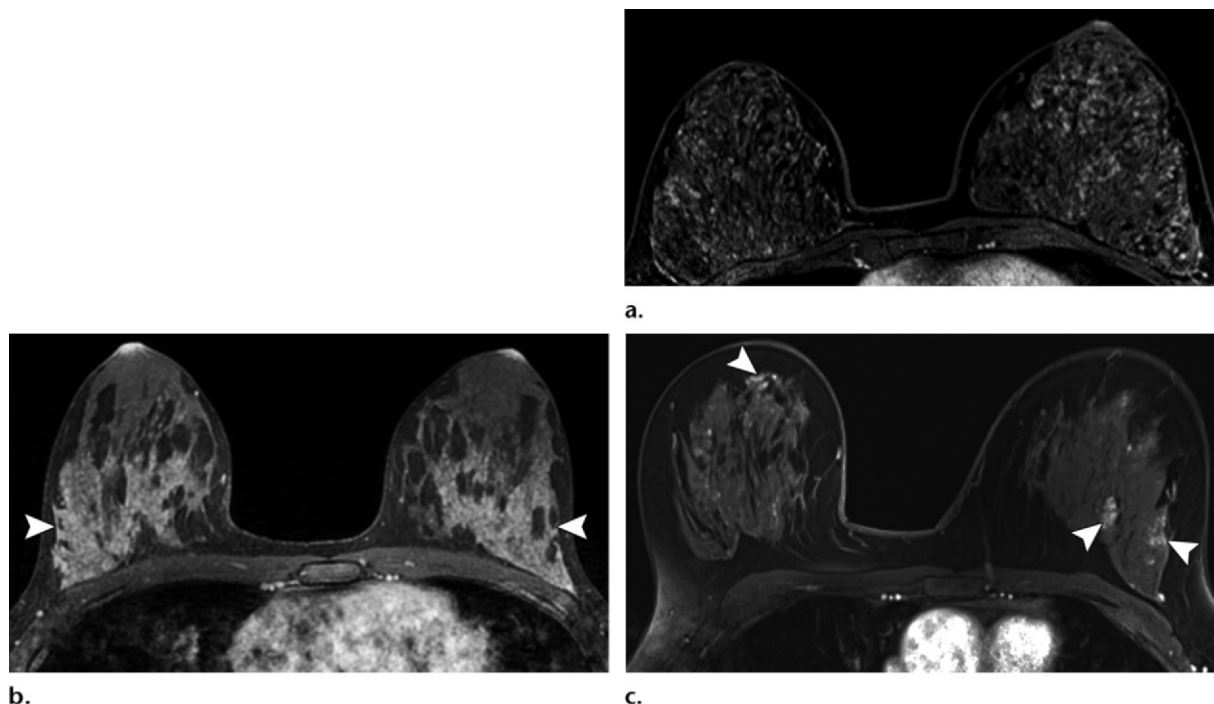


Figure 8. Various distribution patterns of BPE in three different women. **(a)** Axial contrast-enhanced T1-weighted fat-suppressed MR subtraction image shows diffuse, mild to moderate, symmetric, stippled BPE. **(b)** Axial contrast-enhanced T1-weighted fat-suppressed MR image shows bilateral, symmetric, moderate, regional BPE (arrowheads). **(c)** Axial contrast-enhanced T1-weighted fat-suppressed MR image shows multiple foci and focal areas of mild BPE (arrowheads). In the pre-BI-RADS lexicon, this finding was termed *focal and nodular areas of enhancement* (3) or *patchy and nodular BPE* (25).

It is important for the radiologist who is interpreting breast MR imaging studies to be aware of the variety of endogenous and exogenous influences on BPE. A review of the patient's medical and treatment history can provide clarity to equivocal or waxing and waning areas of enhancement.

Does BPE Correlate with the Amount of Fibroglandular Tissue?

A number of authors have attempted to correlate the degree of BPE at MR imaging with the amount of fibroglandular tissue at mammography, with variable results. Several authors found no correlation between BPE and mammographic density (23,24) when imaging was performed in the first part of the menstrual cycle. However, other authors who did not limit imaging to the optimal time of the menstrual cycle (days 7–15) reported that less-dense breasts (BI-RADS categories 1 and 2) were associated with less BPE (25,26). Certainly there are many influences on the degree of BPE seen at breast MR imaging beyond the amount of fibroglandular tissue within the breast. It is important to be aware that breasts with different fibroglandular densities may exhibit minimal, mild, moderate, or marked background enhancement depending on a variety of patient factors.

Common Patterns of BPE

The most typical pattern of normal BPE is bilateral, fairly symmetric, and diffuse, with slow minimal or mild early enhancement and persistent delayed enhancement. In an early work, Kuhl et al (3) reported both diffuse and more focal or “nodular” distributions of background enhancement. In that study, the mean size of enhancing areas of parenchyma was 9–10 mm, which is well above the defined size for an enhancing focus (BI-RADS MR imaging lexicon) and within the size range of a “nodule” or *mass* (the corresponding BI-RADS term). **In addition to the previously described pattern of vascular inflow or picture framing, common internal distribution patterns of BPE include scattered or innumerable similar foci of enhancement (Fig 8a), more geographic areas of symmetric regional enhancement (Fig 8b), and multiple foci and larger focal areas of enhancement (Fig 8c).** In our experience, it is this last pattern that causes more diagnostic difficulty at high-risk screening (Fig 9) because some of the larger focal areas of BPE appear similar to small masses or focal areas of NME (4). When some areas show indeterminate or suspicious kinetic features, short-interval follow-up (or, less often, biopsy) may be necessary. The bilaterality of an enhancement pattern is quite helpful in

Teaching
Point

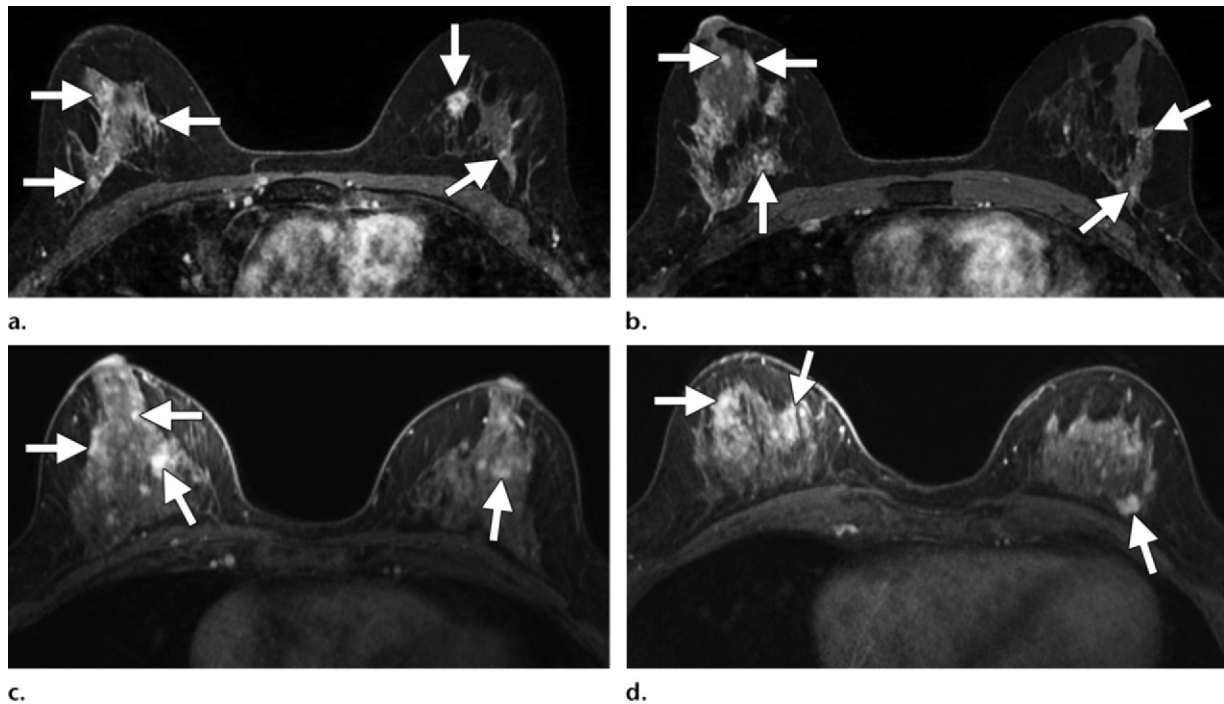


Figure 9. Moderate BPE with a distribution pattern of multiple foci and focal areas of enhancement in two different women. (**a, b**) Screening axial contrast-enhanced T1-weighted fat-suppressed MR images of a 49-year-old woman show multiple foci and larger focal areas of BPE (arrows), findings initially assessed as BI-RADS 3. Findings at follow-up imaging have been stable for more than 2 years. (**c, d**) Screening axial contrast-enhanced T1-weighted fat-suppressed MR images in a 49-year-old woman show multiple foci and focal areas of BPE (arrows). The findings were initially assessed as BI-RADS 3; findings at follow-up imaging have been stable to diminished for more than 2 years.

Teaching Point

interpretation. **Bilateral similar areas of enhancement, regardless of distribution, are more characteristic of benign enhancement, such as fibrocystic changes or hormonally mediated background enhancement, than of malignancy** (3,5,27). Bilateral diffuse or multiple areas of regional enhancement at MR imaging have been compared with diffuse or scattered mammographic calcifications in terms of their diagnostic implication (5). Most often the enhancement seen in this pattern of BPE is minimal to mild in overall degree (Fig 1a, 1b) with slow early and persistent delayed kinetic features (Fig 2). Sometimes the BPE pattern varies over time in the same patient (Fig 10); in high-risk patients, comparison with prior MR imaging studies can be invaluable and has been shown to decrease short-interval follow-up recommendations (28).

There is little in the radiology literature regarding the different distribution patterns of BPE. In a recent study of parenchymal enhancement patterns seen at MR imaging of 229 high-risk asymptomatic women, Jansen et al (29) attempted to characterize kinetic and distribution patterns of BPE and relate them to breast tissue density as assessed on MR images (not on mammograms). The authors assessed the degree of BPE as minimal, mild, moderate, or marked.

They also applied their own classification scheme to evaluate the pattern of BPE (or *parenchymal enhancement pattern* in their terminology) as homogeneous, heterogeneous, or nodular (multiple foci). They found no significant differences in the distribution of BPE according to breast density, but younger women in their study were more likely to have moderate or marked BPE and a nodular pattern of BPE. In a recent intriguing study, King et al (30) found that higher degrees of BPE in high-risk patients who underwent screening MR imaging were associated with significantly increased odds of breast cancer. The precise physiologic reasons for this association remain unclear. Further work is needed to elucidate the prognostic significance of increased BPE in the risk assessment of women who undergo screening MR imaging.

Atypical Patterns of BPE

BPE may manifest with an asymmetric, focal, or regional distribution (1). Enhancement is occasionally moderate or marked in degree and may demonstrate rapid early contrast agent uptake. It is unusual for BPE to demonstrate delayed plateau or washout kinetic curves; however, these more suspicious kinetic curves have been reported (5,27,31,32) in benign mastopathic

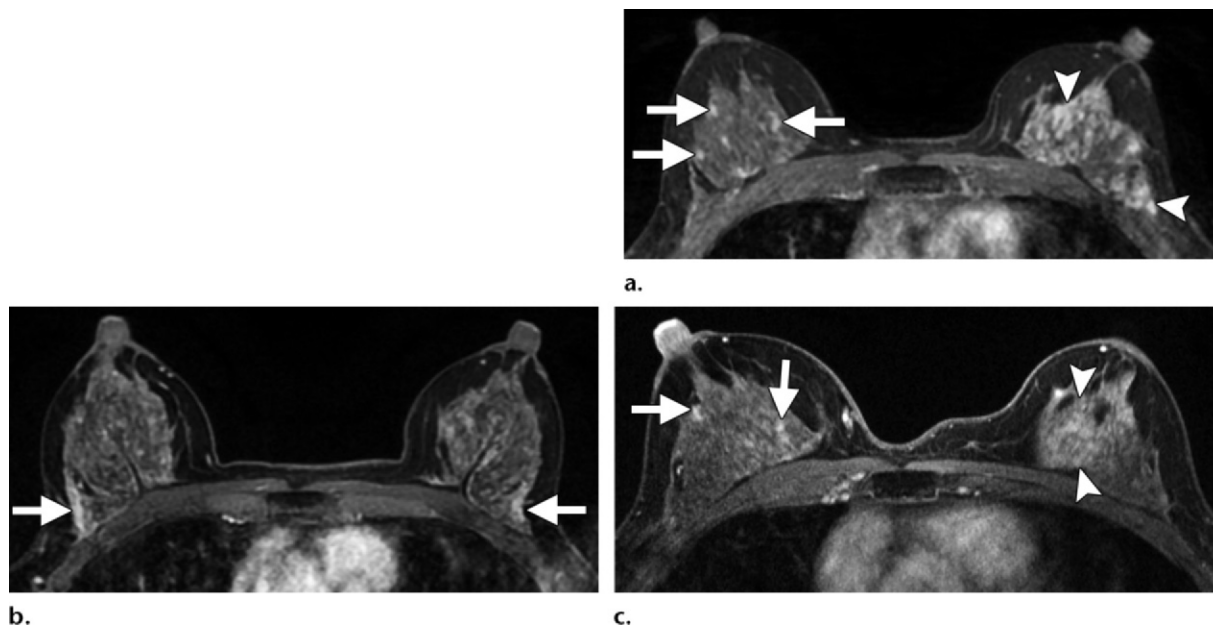
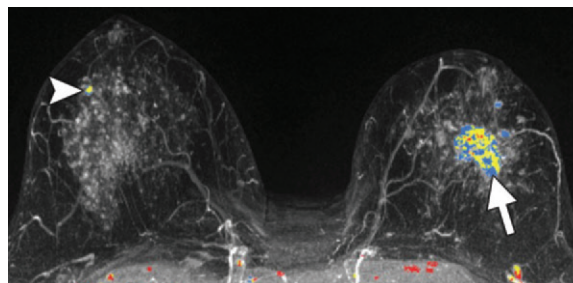


Figure 10. Variable patterns of BPE in a woman who is a *BRCA2* mutation carrier who undergoes yearly high-risk screening MR imaging. **(a)** Axial contrast-enhanced T1-weighted fat-suppressed MR image obtained in 2009 shows stippled BPE in the right breast (arrows) and more regional asymmetric enhancement in the left breast (arrowheads). **(b)** Axial contrast-enhanced T1-weighted fat-suppressed MR image obtained in 2010 shows decreased BPE since 2009 with bilateral picture framing (arrows). **(c)** Axial contrast-enhanced T1-weighted fat-suppressed MR image obtained in 2011 shows increased BPE, similar to that shown in **a**, with stippled pattern in the right breast (arrows) and regional pattern in the left breast (arrowheads).

Figure 11. Preoperative MR imaging performed to evaluate the extent of disease in a 49-year-old woman. Maximum intensity projection image shows a recently diagnosed 3.4-cm invasive lobular cancer in the left breast (arrow), bilateral marked stippled enhancement, and an enhancing focus in the right breast (arrowhead) with isolated suspicious kinetic features (rapid early and delayed washout), findings assessed as BI-RADS 4A. An MR imaging-guided core-needle biopsy of the focus demonstrated sclerosing adenosis.



conditions such as focal fibrocystic areas and sclerosing adenosis, and these underlying benign histologic entities may be present within uninvolved normal enhancing tissue. **In the setting of moderate or marked BPE, a focus or focal area that is dominant or enlarging or that has isolated suspicious kinetic features (Fig 11) should raise more concern than numerous similar findings (Fig 12).**

Asymmetric BPE

After Breast Cancer Treatment.—In premenopausal patients with previously treated breast cancer, BPE will be unilateral after mastectomy and asymmetric after breast conservation therapy (4). Li et al (33) reviewed MR imaging findings in patients who had undergone breast conservation therapy with radiation therapy. In their study, they

confirmed a decrease in BPE and in cystic alteration after breast conservation therapy. Although greater decreases in BPE were seen in the treated breast, decreased BPE also was seen in the untreated breast, a finding that suggests a systemic effect (from endocrine therapy or chemotherapy) as well as a localized decrease in vascularity due to radiation therapy to the treated breast. It is worth noting that the mean and median age of patients in their study was 49.7 years and 49 years, respectively. In many patients in their 40s and early 50s, chemotherapeutic treatment of breast cancer induces menopause, and the decrease in cyclical hormonal levels likely accounts for some of the bilateral effect on BPE seen after cancer treatment. In young women treated for breast cancer, if menopause is not induced by treatment, the contralateral breast may continue to show moderate or marked degrees of BPE (Fig 13). When BPE in

Figure 12. Marked BPE at screening MR imaging in a 47-year-old woman with a family history of breast cancer. Maximum intensity projection image with color overlay (**a**) and axial contrast-enhanced T1-weighted fat-suppressed MR image (**b**) show bilateral innumerable enhancing foci, some with rapid early and delayed washout kinetic features. The lack of dominant or distinguishing features and symmetry are consistent with marked BPE.

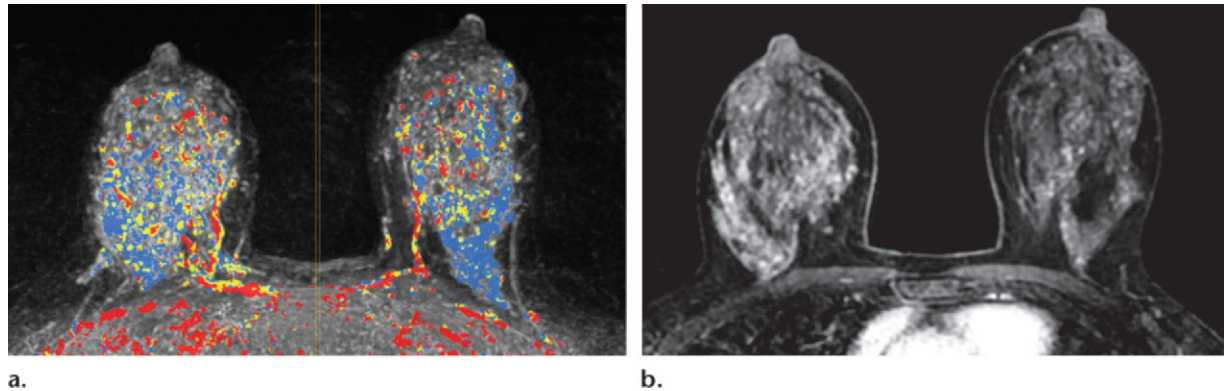
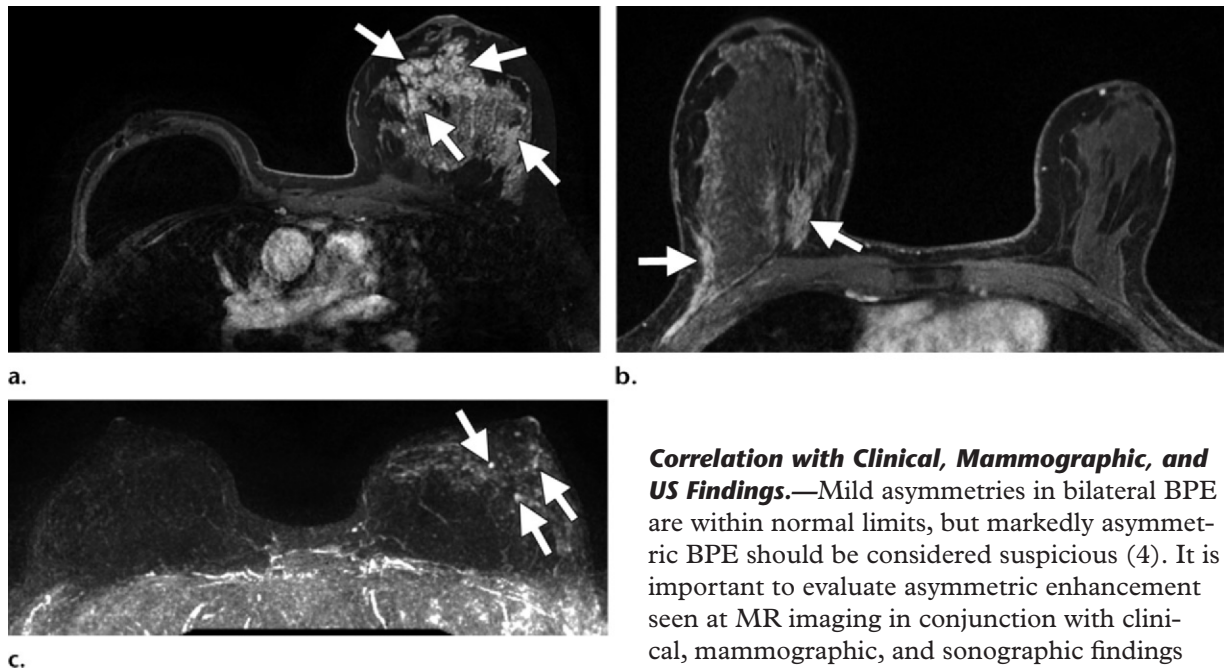


Figure 13. Various patterns of BPE in the untreated breast of three different young premenopausal women with previously treated breast cancer. (**a**) Axial contrast-enhanced T1-weighted fat-suppressed MR image of a 34-year-old woman with previous right ductal carcinoma in situ in 2003 that was treated with breast conservation therapy and radiation therapy and a recurrence in 2006 that was treated with right mastectomy shows marked diffuse BPE (arrows) in the untreated left breast. (**b**) Axial contrast-enhanced T1-weighted fat-suppressed MR image of a 37-year-old woman with previous invasive cancer in the left breast in 2004 that was treated with lumpectomy and radiation therapy shows picture framing (arrows) in the lateral and medial portions of the untreated right breast. (**c**) Maximum intensity projection image of a 37-year-old woman with previous right ductal carcinoma in situ that was treated with lumpectomy and radiation therapy in 2007 shows stippled BPE (arrows) in the untreated left breast.



the untreated breast is focal or regional in distribution, diagnostic difficulties may occur (4) (Fig 14). In this scenario, if an MR imaging finding is considered suspicious but focal BPE is still a differential possibility, it can be very helpful to deliberately schedule MR imaging-guided core-needle biopsy during days 7–15 of the menstrual cycle to minimize hormonally mediated BPE.

Correlation with Clinical, Mammographic, and US Findings.—Mild asymmetries in bilateral BPE are within normal limits, but markedly asymmetric BPE should be considered suspicious (4). It is important to evaluate asymmetric enhancement seen at MR imaging in conjunction with clinical, mammographic, and sonographic findings because correlative findings should elevate suspicion (Fig 15). It has been reported that diagnostic performance improves when NME seen at MR imaging is correlated with mammographic and sonographic findings (31).

False-Positive Interpretation

When BPE is bilateral and symmetric, it is unlikely that the enhancement pattern will lead to a false-positive imaging interpretation. However, when BPE is more focal, regional, or asymmetric,

Figure 14. Focal area of BPE interpreted as NME in a 34-year-old woman with a previous contralateral mastectomy who underwent screening MR imaging on day 19 of the menstrual cycle. Sagittal delayed contrast-enhanced T1-weighted fat-suppressed MR image shows a new solitary focal area of heterogeneous NME (arrow) with medium persistent kinetic features, a finding assessed as BI-RADS 4A. A biopsy was deliberately scheduled for the 2nd week of the menstrual cycle to minimize BPE; the enhancement had resolved on the day of biopsy and the biopsy was cancelled. The enhancement was not depicted at 6-month surveillance MR imaging.

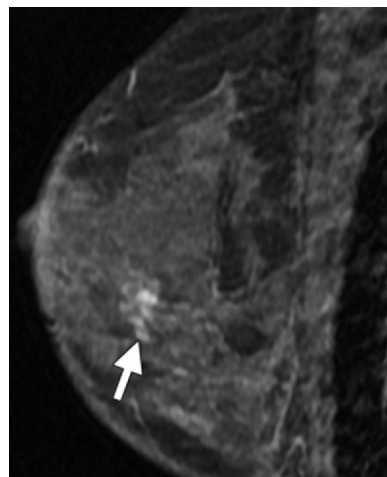
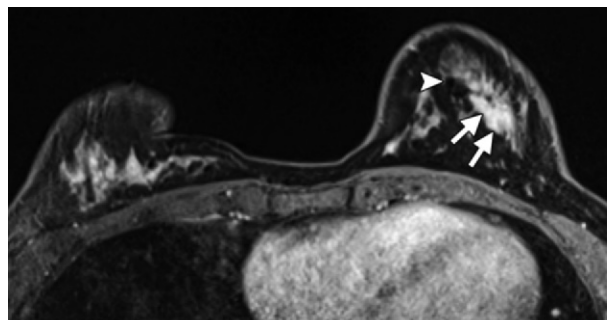
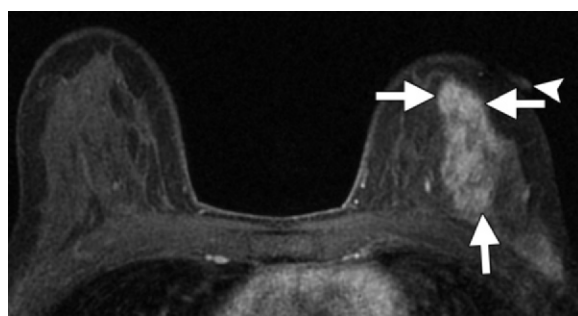
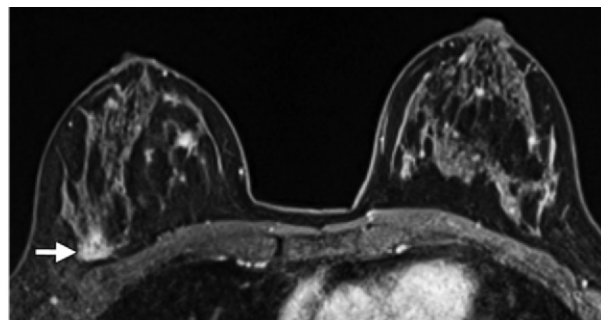


Figure 15. Asymmetric BPE in a 43-year-old woman who presented with pain and palpable fullness in the upper outer left breast. Findings from mammography and US were unrevealing. Axial contrast-enhanced T1-weighted fat-suppressed MR image shows diffuse asymmetric regional homogeneous enhancement (arrows). A fiducial marker (arrowhead) marks the site of a palpable finding found at clinical breast examination. An MR imaging-guided core-needle biopsy demonstrated focal columnar cell change, epithelial hyperplasia, and fibroadenomatoid change.



a.



b.

Figure 16. False-positive MR imaging interpretation due to moderate BPE in a 42-year-old woman with recently diagnosed cancer in the left breast who underwent preoperative MR imaging on day 23 of the menstrual cycle to evaluate the extent of disease. **(a)** Axial contrast-enhanced T1-weighted fat-suppressed MR image shows a biopsy clip (arrowhead) and NME (arrows) representing the known cancer at the 6-o'clock position in the left breast. **(b)** Axial contrast-enhanced T1-weighted fat-suppressed MR image shows focal BPE in the posterior lateral portion of the right breast (arrow) that was interpreted as NME, demonstrated medium persistent kinetic features, and was assessed as BI-RADS 4. An MR imaging-guided core-needle biopsy demonstrated normal breast tissue.

it has been reported to be associated with a higher likelihood of a BI-RADS 3 assessment (probably benign, short-interval follow-up) (25,28) in the screening setting. When BPE manifests with a more focal, asymmetric, or regional distribution, it may be hard to distinguish from NME (4). If the enhancement pattern is interpreted as NME rather than as BPE, the radiologist must consider the possibility of malignancy (Fig 14). Transient areas of BPE have been reported to be a factor in

the cancellation of MR imaging-guided core biopsies; Brennan et al (34) reported that moderate or marked BPE was associated with a significantly higher MR imaging-guided core biopsy cancellation rate compared with that for minimal or mild BPE.

When diagnostic MR imaging is performed to evaluate the extent of disease in a patient with newly diagnosed cancer, BPE can also lead to a false-positive interpretation (Figs 16, 17). In a

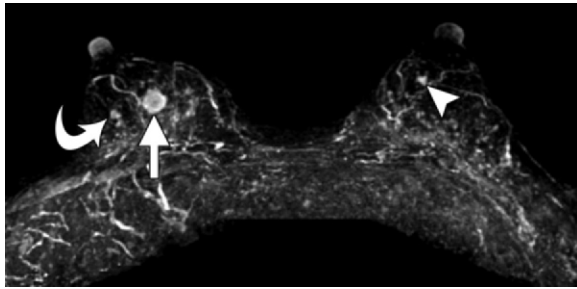


Figure 17. False-positive interpretation due to marked BPE in a 50-year-old premenopausal woman with recently diagnosed cancer in the right breast who underwent diagnostic MR imaging during the 4th week of the menstrual cycle to evaluate the extent of disease. Maximum intensity projection image shows marked BPE with innumerable foci, the known cancer in the right breast (straight arrow), an adjacent mass in the right breast (curved arrow) that was considered suspicious for a satellite lesion, and a small mass in the left breast (arrowhead), all with rapid early and delayed washout kinetic curves. MR imaging-guided core-needle biopsy of the left breast mass demonstrated invasive lobular cancer. MR imaging-guided core-needle biopsy of the small mass lateral to the known cancer in the right breast demonstrated benign columnar cell change, microcysts, and fibroadenomatoid change.

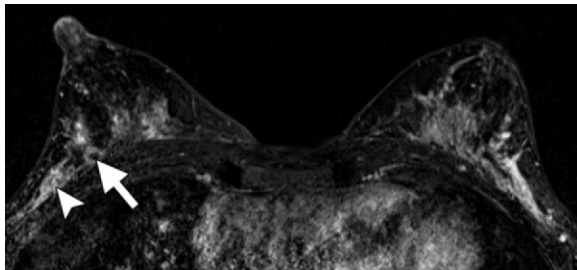


Figure 18. Potential false-negative interpretation due to marked BPE in a 38-year-old woman with newly diagnosed cancer in the right breast. Four subcentimeter malignant masses (one palpable) were visible in the 8:30 to 9-o'clock position at US (not shown). Axial contrast-enhanced T1-weighted fat-suppressed MR subtraction image shows marked BPE; known malignant lesions are difficult to perceive against BPE. A biopsy clip (arrow) marks one of the lesions. The arrowhead marks another extremely subtle lesion within the lateral BPE; this lesion would have been missed if the MR imaging findings had not been correlated with the US findings.

recent study, DeMartini et al (35) assessed the impact of varying degrees of BPE on the interpretation of breast MR imaging studies in a variety of clinical situations, including high-risk screening, evaluation of the extent of disease in patients with newly diagnosed cancer, problem solving, short-term follow-up, evaluation of disease response to neoadjuvant chemotherapy, and a small number of other indications. They found that although higher amounts of BPE were associated with higher rates

of abnormal interpretation (BI-RADS 0, 3, 4, or 5), there was no significant difference in the positive biopsy rate, cancer yield, sensitivity, or specificity. These authors did not individually assess the impact of BPE on diagnostic performance for specific subgroups of patients. The impact of BPE on diagnostic accuracy may be different for high-risk screening compared with the imaging of patients with newly diagnosed cancer. False-positive MR imaging interpretation accounts for some of the reluctance of breast surgeons to use MR imaging to evaluate the extent of disease (36).

False-Negative Interpretation

Breast MR imaging is highly sensitive for the detection of breast cancer. However, in the setting of moderate or marked BPE, it is possible that a small mass or a larger area of NME may be masked by adjacent enhancing breast tissue (Fig 18). This is analogous to dense fibroglandular tissue that may obscure a cancerous lesion at mammography. In fact, several studies that reported cancerous lesions that were undetected at MR imaging have indicated that BPE was a factor in false-negative interpretation (37–39).

Conclusion

BPE seen at breast MR imaging is common and, when bilateral and diffuse, should cause no diagnostic dilemma, even if it is moderate or marked in degree, as long as it is homogeneous or stippled in internal enhancement pattern and diffuse or regional in distribution. A pattern of BPE that includes multiple foci and larger focal areas of enhancement may be problematic, particularly at high-risk screening or in the assessment of disease extent in patients with newly diagnosed breast cancer. This is because the larger focal areas of BPE seen in this pattern can overlap in appearance with focal areas of NME. If a focal area of BPE is interpreted as NME, it then is viewed as a breast lesion that requires assessment and management. Multiplicity of findings and bilaterality of findings are more characteristic of BPE and are helpful features for interpretation. When an equivocal focal area of enhancement is seen in the setting of BPE, unique kinetic features, a truly dominant size, or interval change should prompt biopsy. In nonsurgical (ie, screening) cases, 6-month follow-up MR imaging is an alternative to biopsy when BPE is favored over a pathologic process.

Radiologists who are interpreting breast MR imaging studies should be familiar with the normal vascular inflow patterns of breast tissue enhancement; the variable patterns of BPE; the endogenous and exogenous hormonal influences on BPE; the possibility of false-positive and false-negative MR imaging interpretations due to focal

or diffuse BPE; and the importance of interpreting MR imaging studies in conjunction with mammographic, sonographic, and clinical findings to maximize accuracy.

Disclosures of Conflicts of Interest.—**C.S.G.:** *Financial activities not related to the present article:* program reviewer for American College of Radiology Mammography Accreditation; lecturer for National Diagnostic Imaging Symposium, Kaiser-Permanente, and New York Breast Imaging Society. **R.L.B.:** *Financial activities not related to the present article:* royalties from Amirsys. **S.R.:** *Financial activities not related to the present article:* royalties from Amirsys.

References

- Morris EA. Diagnostic breast MR imaging: current status and future directions. *Radiol Clin North Am* 2007;45(5):863–880, vii.
- Ikeda DM, Hylton NM, Kuhl CK, et al. BI-RADS: magnetic resonance imaging, 1st ed. In: D'Orsi CJ, Mendelson EB, Ikeda DM, et al, eds. *Breast Imaging Reporting and Data System: ACR BI-RADS—breast imaging atlas*. Reston, Va: American College of Radiology, 2003; 1–114.
- Kuhl CK, Bieling HB, Gieseke J, et al. Healthy premenopausal breast parenchyma in dynamic contrast-enhanced MR imaging of the breast: normal contrast medium enhancement and cyclical-phase dependency. *Radiology* 1997;203(1):137–144.
- Giess CS, Raza S, Birdwell RL. Patterns of non-masslike enhancement at screening breast MR imaging of high-risk premenopausal women. *Radiographics* 2013;33(5):1343–1360.
- Kuhl C. The current status of breast MR imaging. I. Choice of technique, image interpretation, diagnostic accuracy, and transfer to clinical practice. *Radiology* 2007;244(2):356–378.
- Romrell LJ, Bland KI. Anatomy of the breast, axilla, chest wall, and related metastatic sites. In: Bland KI, Copeland EM III, eds. *The breast: comprehensive management of benign and malignant disorders*. 3rd ed. Philadelphia, Pa: Saunders, 2004; 21–42.
- Birdwell RL, Raza S, Odulate AS. NMLE: diffuse, background enhancement. In: Raza S, Birdwell RL, eds. *Specialty imaging: breast MRI—a comprehensive imaging guide*. Salt Lake City, Utah: Amirsys, 2010; II-3-84–II-3-99.
- Müller-Schimpfle M, Ohmenhäuser K, Stoll P, Dietz K, Claussen CD. Menstrual cycle and age: influence on parenchymal contrast medium enhancement in MR imaging of the breast. *Radiology* 1997; 203(1):145–149.
- Delille JP, Slanetz PJ, Yeh ED, Kopans DB, Garrido L. Physiologic changes in breast magnetic resonance imaging during the menstrual cycle: perfusion imaging, signal enhancement, and influence of the T1 relaxation time of breast tissue. *Breast J* 2005;11(4): 236–241.
- Ellis RL. Optimal timing of breast MRI examinations for premenopausal women who do not have a normal menstrual cycle. *AJR Am J Roentgenol* 2009;193(6):1738–1740.
- Talele AC, Slanetz PJ, Edmister WB, Yeh ED, Kopans DB. The lactating breast: MRI findings and literature review. *Breast J* 2003;9(3):237–240.
- Espinosa LA, Daniel BL, Vidarsson L, Zakhour M, Ikeda DM, Herfkens RJ. The lactating breast: contrast-enhanced MR imaging of normal tissue and cancer. *Radiology* 2005;237(2):429–436.
- Taylor D, Lazberger J, Ives A, Wylie E, Saunders C. Reducing delay in the diagnosis of pregnancy-associated breast cancer: how imaging can help us. *J Med Imaging Radiat Oncol* 2011;55(1):33–42.
- Kubik-Huch RA, Gottstein-Aalame NM, Frenzel T, et al. Gadopentetate dimeglumine excretion into human breast milk during lactation. *Radiology* 2000; 216(2):555–558.
- American College of Radiology manual on contrast media, version 8, 2012; 79–80. <http://www.nxtbook.com/nxtbooks/acr/contrastmediamanual2012/>. Accessed March 5, 2013.
- King V, Gu Y, Kaplan JB, Brooks JD, Pike MC, Morris EA. Impact of menopausal status on background parenchymal enhancement and fibroglandular tissue on breast MRI. *Eur Radiol* 2012;22(12): 2641–2647.
- Pfleiderer SOR, Sachse S, Sauner D, et al. Changes in magnetic resonance mammography due to hormone replacement therapy. *Breast Cancer Res* 2004; 6(3):R232–R238.
- Delille JP, Slanetz PJ, Yeh ED, Kopans DB, Halpern EF, Garrido L. Hormone replacement therapy in postmenopausal women: breast tissue perfusion determined with MR imaging—initial observations. *Radiology* 2005;235(1):36–41.
- King V, Kaplan J, Pike MC, et al. Impact of tamoxifen on amount of fibroglandular tissue, background parenchymal enhancement, and cysts on breast magnetic resonance imaging. *Breast J* 2012;18(6): 527–534.
- Oksa S, Parkkola R, Luukkaala T, Mäenpää J. Breast magnetic resonance imaging findings in women treated with toremifene for premenstrual mastalgia. *Acta Radiol* 2009;50(9):984–989.
- King V, Goldfarb SB, Brooks JD, et al. Effect of aromatase inhibitors on background parenchymal enhancement and amount of fibroglandular tissue at breast MR imaging. *Radiology* 2012;264(3): 670–678.
- Mousa NA, Eiada R, Crystal P, Nayot D, Casper RF. The effect of acute aromatase inhibition on breast parenchymal enhancement in magnetic resonance imaging: a prospective pilot clinical trial. *Menopause* 2012;19(4):420–425.
- Cubuk R, Tasali N, Narin B, Keskiner F, Celik L, Guney S. Correlation between breast density in mammography and background enhancement in MR mammography. *Radiol Med (Torino)* 2010;115(3):434–441.
- Ko ES, Lee BH, Choi HY, Kim RB, Noh WC. Background enhancement in breast MR: correlation with breast density in mammography and background echotexture in ultrasound. *Eur J Radiol* 2011;80(3):719–723.
- Hambly NM, Liberman L, Dershaw DD, Brennan S, Morris EA. Background parenchymal enhancement on baseline screening breast MRI: impact on biopsy rate and short-interval follow-up. *AJR Am J Roentgenol* 2011;196(1):218–224.
- Uematsu T, Kasami M, Watanabe J. Should breast MRI be performed with adjustment for the phase in patients' menstrual cycle? Correlation between mammographic density, age, and background enhancement on breast MRI without adjusting for the phase in patients' menstrual cycle. *Eur J Radiol* 2012;81(7):1539–1542.

27. Agrawal G, Su MY, Nalcioglu O, Feig SA, Chen JH. Significance of breast lesion descriptors in the ACR BI-RADS MRI lexicon. *Cancer* 2009;115(7):1363–1380.
28. Abramovici G, Mainiero MB. Screening breast MR imaging: comparison of interpretation of baseline and annual follow-up studies. *Radiology* 2011;259(1):85–91.
29. Jansen SA, Lin VC, Giger ML, Li H, Karczmar GS, Newstead GM. Normal parenchymal enhancement patterns in women undergoing MR screening of the breast. *Eur Radiol* 2011;21(7):1374–1382.
30. King V, Brooks JD, Bernstein JL, Reiner AS, Pike MC, Morris EA. Background parenchymal enhancement at breast MR imaging and breast cancer risk. *Radiology* 2011;260(1):50–60.
31. Thomassin-Naggara I, Trop I, Chopier J, et al. Non-masslike enhancement at breast MR imaging: the added value of mammography and US for lesion categorization. *Radiology* 2011;261(1):69–79.
32. Chen JH, Liu H, Baek HM, Nalcioglu O, Su MY. Magnetic resonance imaging features of fibrocystic change of the breast. *Magn Reson Imaging* 2008;26(9):1207–1214.
33. Li J, Dershaw DD, Lee CH, Joo S, Morris EA. Breast MRI after conservation therapy: usual findings in routine follow-up examinations. *AJR Am J Roentgenol* 2010;195(3):799–807.
34. Brennan SB, Sung JS, Dershaw DD, Liberman L, Morris EA. Cancellation of MR imaging-guided breast biopsy due to lesion nonvisualization: frequency and follow-up. *Radiology* 2011;261(1):92–99.
35. DeMartini WB, Liu F, Peacock S, Eby PR, Gutierrez RL, Lehman CD. Background parenchymal enhancement on breast MRI: impact on diagnostic performance. *AJR Am J Roentgenol* 2012;198(4):W373–W380.
36. Houssami N, Morrow M. Pre-operative breast MRI in women with recently diagnosed breast cancer: where to next? *Breast* 2010;19(1):1–2.
37. Teifke A, Hlawatsch A, Beier T, et al. Undetected malignancies of the breast: dynamic contrast-enhanced MR imaging at 1.0 T. *Radiology* 2002;224(3):881–888.
38. Shimauchi A, Jansen SA, Abe H, Jaskowiak N, Schmidt RA, Newstead GM. Breast cancers not detected at MRI: review of false-negative lesions. *AJR Am J Roentgenol* 2010;194(6):1674–1679.
39. Uematsu T, Kasami M, Watanabe J. Does the degree of background enhancement in breast MRI affect the detection and staging of breast cancer? *Eur Radiol* 2011;21(11):2261–2267.

Background Parenchymal Enhancement at Breast MR Imaging: Normal Patterns, Diagnostic Challenges, and Potential for False-Positive and False-Negative Interpretation

Catherine S. Giess, MD • Eren D. Yeh, MD • Sughra Raza, MD • Robyn L. Birdwell, MD

RadioGraphics 2014; 34:234–247 • Published online 10.1148/rg.341135034 • Content Codes: **BR** **MR**

Page 236

Therefore, BPE commonly begins in the periphery of the lateral, medial, posterior, superior, and inferior breast tissue and gradually becomes apparent in the more central breast tissue.

Pages 238

It is recommended that nonurgent breast MR imaging (such as screening or short-term follow-up imaging) should be scheduled during the 2nd week of the menstrual cycle (days 7–15).

Page 240

In addition to the previously described pattern of vascular inflow or picture framing, common internal distribution patterns of BPE include scattered or innumerable similar foci of enhancement, more geographic areas of symmetric regional enhancement, and multiple foci and larger focal areas of enhancement.

Page 241

Bilateral similar areas of enhancement, regardless of distribution, are more characteristic of benign enhancement, such as fibrocystic changes or hormonally mediated background enhancement, than of malignancy.

Page 242

In the setting of moderate or marked BPE, a focus or focal area that is dominant or enlarging or that has isolated suspicious kinetic features should raise more concern than numerous similar findings.